

OCULAR Outlook

A PUBLICATION FOR THE VETERINARY COMMUNITY FROM EYE CARE FOR ANIMALS

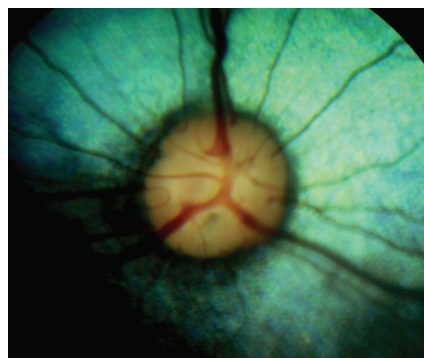
IMMUNE RETINITIS AND SARDS

by **Christin Fahrner, DVM, MS, DACVO**

Many clinicians have encountered patients that present for evaluation with sudden vision loss without discomfort. Initial diagnostics indicate these patients are free from glaucoma, evident optic neuritis, or substantial retinal changes consistent with retinal atrophy or detachment. Two distinctively labeled but yet very similar conditions have been reported in canine patients in which patients present with a sudden history of blindness without pain including sudden acquired retinal degeneration syndrome (SARDS) and more recently, a condition termed immune-mediated retinitis (IMR). Some of these patients, in addition to sudden vision loss, have clinical signs consistent with Cushing's syndrome or hyperadrenocorticism including increased panting, thirst, and polyphagia.

On ophthalmic examination of SARDS patients, the menace response is absent, and the dazzle reflex (blink response to bright white light) is typically present, as are the pupillary light reflexes

(PLRs). The IMR patients also have a negative menace response, but a positive dazzle reflex, and direct and consensual PLRs with bright light.



Normal Canine Fundus

Posterior segment evaluation with both SARDS and IMR may be normal in their acute phases, although some dogs may have mild funduscopic changes. Patchy areas of altered tapetal reflectivity can be detected in subacute stages, becoming more diffusely hyper-reflective over time with retinal thinning resembling other degenerative diseases of the retina in time.

The gold standard for differentiating retinal causes for vision loss from central or brain-related causes of vision loss is electroretinography (ERG). Normal retinal function in a blind patient with appropriate, although perhaps sluggish, direct and consensual PLRs is suggestive of central abnormalities resulting in vision loss. Extinguished or absent retinal function on ERG indicates that the cause for vision loss is at

the level of the retina within the eye. Some feel that SARDS patients always have absent electrical function on ERG, and it has been proposed that IMR patients can have diminished or asymmetric changes on ERG as a differentiating feature of each disease. However, the duration of the disease process could impact the photoreceptor activity, therefore extinguished function on ERG could be consistent with SARDS or IMR.

It is possible that there could be central abnormalities concurrent with retinal dysfunction (neoplasia or inflammatory changes), but it is unlikely that both lesions involving the central vision pathways and abnormal retinal function would be present in the same patient where both conditions were directly contributing to concurrent vision loss. While there is ongoing research as to the etiopathogenesis of SARDS and IMR, it is suspected that an underlying abnormality such as inflammatory disease or neoplasia could trigger an abnormal immune response (autoimmune response) that is misdirected toward the retina.

(CONTINUED ON PAGE 2)



Christin Fahrner, DVM, MS, DACVO

INSIDE THIS ISSUE

Locations	p. 2
New Doctors	p. 3 & 4
Congratulations	p. 4 & 5
Retinal Detachment Surgery	p. 5
Spotlight	p. 5
Message from the President	p. 6

OCULAR *Outlook*

Editor: Christin Fahrer
DVM, MS, DACVO
Managing Editor: Debbie Brinkoetter

Eye Care for Animals welcomes your comments on Ocular Outlook. Please e-mail your feedback to dbrinkoetter@eyecareforanimals.com or call Debbie at (480) 682-6911.

For electronic subscription please visit www.EyeCareForAnimals.com

Eye Care for Animals

LOCATIONS

- Arizona** Avondale • East Tucson • Gilbert • Phoenix • Scottsdale • South Scottsdale • Tucson
- California** Corte Madera • Culver City • El Cerrito • La Mesa • Palm Desert • Pasadena • San Diego • San Juan Capistrano • Santa Rosa • Torrance • Tustin • Upland • Woodland Hills
- Connecticut** Norwalk
- Florida** Tampa • Lakeland
- Illinois** Chicago • St. Charles • Wheeling
- Kansas** Mission • Overland Park • Wichita
- Maryland** Annapolis (Bestgate Rd) • Annapolis (Defense Hwy) • Bel Air • Columbia • Frederick • Rockville • Towson
- Missouri** Lee's Summit • Springfield
- Nevada** Las Vegas • Reno
- New Mexico** Albuquerque • Santa Fe
- Ohio** Akron • Cleveland
- Rhode Island** Warwick
- Texas** Austin • El Paso • Houston • Round Rock • The Woodlands
- Utah** Salt Lake City • Sunset
- Virginia** Leesburg
- Wisconsin** Pewaukee

IMMUNE RETINITIS AND SARDS (CONTINUED FROM PAGE 1)

Another tool that may be utilized in the diagnosis of SARDS or IMR would be the use of red and blue lights of specific wavelengths to stimulate the photoreceptors (rods and cones) and a photosensitive pigment called melanopsin located in the retinal ganglion cells. In SARDS and IMR patients, if a red light of a specific wavelength (630 nm) is utilized to assess PLRs, there is a negative response (no direct PLR). This is due to absent photoreceptor activity (rods and cones). In the same patient with IMR or SARDS, there is a positive response (direct PLR) when blue light of a specific wavelength (480 nm) is utilized, because the photosensitive pigment melanopsin is present in retinal ganglion cells; stimulation of these cells can trigger a PLR without normal photoreceptor activity.

Lastly, some promote sex steroid and hormone testing in their search for a diagnosis or causative factor(s). This is considered to be somewhat controversial, as many clinicians believe that the clinical signs consistent with Cushing's syndrome or hyperadrenocorticism that accompany the vision changes in these patients are related to increased anxiety triggered by a relatively sudden vision change. Changes in physiologic cortisol may be persistent or transient, therefore may not be reliably elevated on testing, and alterations in cortisol may or may not be accompanied by altered sex steroid levels. To date, there has been no definitive scientific literature linking hormone or sex steroid changes to retinal dysfunction associated with SARDS or IMR. Future research will likely involve further investigation of the suspected autoimmune component of the condition as well as other factors, including an endocrine component.

Treatment of SARDS and IMR typically employs the use of immunomodulating therapies, each of which has its drawbacks depending on dosage and duration of use. Intravenous immunoglobulin (IVIg) can be utilized intravenously or as an intraocular injection. This

therapy is utilized in humans with cancer associated retinopathy (CAR) and although the direct mechanism is unknown, it is thought to reduce autoantibodies involved in immune-mediated conditions. Circulating retinal autoantibodies are not consistently identified in SARDS or IMR cases, nor are they always demonstrated in CAR seen in humans. However, improvement following IVIg has been seen by some clinicians after therapy. In addition to IVIg, other immunomodulating medications are frequently utilized. High doses of corticosteroids were initially recommended in addition to oral doxycycline. However, treating blind patients with high doses of medication that has significant side effects including polydipsia and polyuria can be challenging if not very frustrating for our patients and their caretakers. Other immunomodulating medications such as cyclosporine and leflunomide have also been utilized, each with limitations.

Duration of treatment is also in question; considering more prolonged treatment may be more efficacious than short-term therapy, particularly in light of the fact that the condition may have a longer onset than initially recognized. The disease is thought to be acute in nature because it is most often detected when the patient goes blind. However, the sometimes asymmetrical retinal changes may be indicative of a unilateral condition that has become bilateral and finally culminates in vision loss. To date, there is no known ideal combination of immunomodulating modalities, whether injectable or oral.

It is also important to understand that what is considered to be a successful response to therapy is not the return of what we consider to be normal vision in many patients. A visual patient treated for SARDS or IMR with success may be able to navigate a maze, but typically do not regain a menace response. In

(CONTINUED ON PAGE 4)

WELCOME!

DANIEL BINDER DVM, PHD, DACVO



Dr. Daniel Binder is originally from Long Island, NY. He earned his undergraduate degree in psychobiology from Binghamton University, NY (SUNY). He then completed a PhD in Neuroscience at the University of Virginia in

Charlottesville, VA. Dr. Binder pursued his Doctor of Veterinary Medicine at the Virginia-Maryland Regional College of Veterinary Medicine and completed his residency in Ophthalmology there as well. He previously worked as an intern in small animal surgery and medicine at North Carolina State University's College of Veterinary Medicine.

In 2011, Dr. Binder offered his knowledge and experience at the Virginia-Maryland Regional College of Veterinary Medicine as a clinical instructor of ophthalmology in the Department of Small Animal Clinical and helped develop the department's auxiliary ophthalmology service. He is board certified with the American College of Veterinary Ophthalmologists. After practicing for two years in Annapolis, MD, he joined Eye Care for Animals-Warwick in early 2015.

KYSHIA T. DAVIS DVM, DACVO

Dr. Kyshia Davis is a native of Northern California. She completed her undergraduate coursework at the University of California, Davis and veterinary school at Colorado State



University. Following veterinary school, she completed a one year rotating small animal medicine and surgery internship at Michigan State University followed by a one year internship and a three year residency in comparative ophthalmology at Louisiana State University. Dr. Davis has a special interest in avian and exotic animal ophthalmology as well as tear film, corneal and retinal diseases. In her spare time, Dr. Davis enjoys traveling and spending time with her human and pet family, which includes two Pomeranians and a parrot.

CAREY MCINNIS DVM, MS, DACVO



Dr. Carey McInnis is originally from New Orleans, LA. She received her bachelor's degree in Biology from Huntingdon College in Montgomery, Alabama, after which she graduated from

Auburn University, College of Veterinary Medicine. Dr. McInnis then completed a one-year rotating small animal and surgery internship at the University of Missouri-Columbia, followed by a one-year ophthalmology internship at a private practice in Las Vegas, NV.

She then completed a three-year ophthalmology residency program at Colorado State University - Veterinary Teaching Hospital, while earning a master's degree in clinical sciences.

Dr. McInnis has been practicing veterinary ophthalmology in Maryland since 2010.

ROBERT L. PEIFFER DVM, PHD, DACVO

Dr. Robert L. Peiffer attended the University of Minnesota for his veterinary degrees and became a Diplomate of the AVCO in 1976. He has lectured both nationally and abroad, edited several textbooks and published over 200 articles in refereed journals. Dr. Peiffer has practiced in North Carolina, Virginia, Pennsylvania and New Jersey prior to relocating to the Southwest. He is recognized as a pioneer in phacoemulsification and intraocular lenses in dogs.



In addition, Dr. Peiffer has served as President of the American Society of Veterinary Ophthalmology, the American College of Veterinary Ophthalmologists, the International Society of Veterinary Ophthalmology and the International Society of Ocular Toxicology. Professional recognitions include the Gaines Award for Veterinarian of the Year from the American Animal Hospital Association and career achievement awards from the American Veterinary Medical Association and the World Small Animal Veterinary Association.

MARK SHIFRIN, DVM



Dr. Mark Shifrin is a native Texan originally from El Paso. He received both his Bachelor of Science and Veterinary degrees from Texas A&M University, graduating with honors in 1979. After

graduation, Dr. Shifrin joined a small animal private practice in Abilene Texas where he practiced all aspects of veterinary medicine for 3 years. He was then accepted for and completed a residency program in Veterinary Ophthalmology at the University of California-Davis along with additional training at Stanford University.

Dr. Shifrin relocated to Austin, Texas in 1984 where he opened his own practice, doing business as Austin Animal Eye Clinic for 31 years. His practice included large animals as well as small for the first 15 years, but was limited to small animals the last 16. In addition to Texas, he is also licensed in New Mexico. Dr. Shifrin joined the Eye Care for Animals team in August 2015.

ANNE WEIGT DVM, MS, DACVO

Dr. Anne Weigt is originally from Saginaw, Michigan. She went to Miami University in Oxford, OH and graduated with a degree in Zoology and a degree in English-Technical Writing. After working in research for a few years, in Cincinnati and the Republic of Panama, she went to veterinary school at Ross University in St. Kitts. While not really tired of island life, she did transfer after one year to the University of Tennessee, graduating in



1997. Dr. Weigt completed an internship in small animal medicine and surgery at the Berwyn and Franklin Park VCA hospitals outside of Chicago. Dr. Weigt completed her residency in Ophthalmology at the Virginia-Maryland Regional College of Veterinary Medicine. At the same time, she completed a Masters of Science degree. Dr. Weigt started working in Annapolis, MD at Animal Eye Care in 2001 and merged with Eye Care for Animals in November of 2015. Her professional interests include intraocular surgery, eyelid and facial reconstruction, neuro-ophthalmology and equine ophthalmology.

(CONTINUED ON PAGE 4)

WELCOME (CONTINUED FROM PAGE 3)



**E. DAN WOLF
DVM, DACVO**

Dr. Dan Wolf earned his DVM degree from Ohio State University in 1968 and 5 years later became the first veterinarian accepted for

comparative ophthalmology residency at the University of Illinois Medical College, where his research focused on retinal diseases and cataracts.

In 1976 Dr. Wolf earned his Diplomate status as a 'board certified veterinary ophthalmologist' and was accepted into membership of the American College of Veterinary Ophthalmologists (ACVO). He has since served on the board of directors and as president of the ACVO. He has been a faculty member of both the University of Florida and Ohio State University, where he taught veterinary ophthalmology, and has authored numerous articles for scientific journals and textbooks. Many of the veterinarians in western Florida were Dr. Wolf's students.

Dr. Wolf opened his veterinary ophthalmic referral service, Southern Eye Clinic for Animals in Tampa, FL in 1991. More than 4,000 animals each year receive care from Dr. Wolf, who's had experience with just about the entire animal kingdom including horses, elephants, all manner of birds (even ostriches), tigers and yaks. Dr. Wolf makes house calls to treat large animals that won't make it through the front door of his office and consults with Busch Gardens Animal Park and Lowry Park Zoo in Tampa. Dr. Wolf and his Southern Eye Clinic for Animals practice joined the Eye Care for Animals' team in January, 2015.

**CONGRATULATIONS TO:
OUR NEWEST BOARDED DIPLOMATE**



Rosalie Atkins, DVM, DACVO,
El Cerrito, CA

**RESIDENT GRADUATES
2015**



Michelle Samuel, VMD
Leesburg, VA and Frederick, MD

2016



Kimberly Hsu, DVM, MSc
St. Charles and Wheeling, IL

Clinton Doering, Ph.D., DVM
Tucson, AZ



Francesca Venturi, DVM
Palm Desert and Tustin, CA



IMMUNE RETINITIS AND SARDS

(CONTINUED FROM PAGE 2)

In addition, measurable improvement in retinal function may not be detected in all cases by ERG. The goal of therapy in a pet with suspected IMR that maintains vision in one eye but has lost vision in the contralateral eye would be to prolong vision as long as possible in the clinically unaffected eye.

**Clinical Atlas of
Canine and Feline
Ophthalmic
Disease**



A new book
written by
Douglas Esson
BVSc, MRCVS,
DVM, DACVO

Available via
Wiley.com

RETINAL DETACHMENT SURGERY

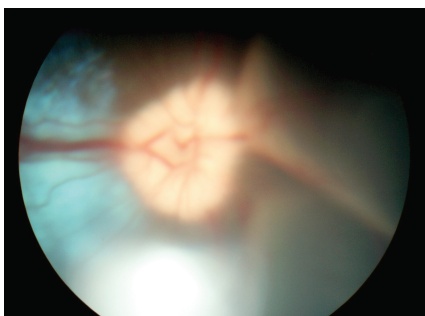
by Allison Hoffman, DVM, DACVO



Allison Hoffman, DVM, DACVO
Fellowship, Vitreo-Retinal Surgery

In veterinary medicine, we understand that the level of animal care has risen to new heights. And during the past decade, veterinary ophthalmology has expanded this progress and expertise to the area of posterior segment eye surgery. Canine patients once left blind with sudden or recent blindness are now given new hope for restoration of sight. Pet guardians are no longer willing to accept that their pet's vision is lost due to an inherited predisposition to retinal detachment. Other times, the retina can detach after cataract surgery or from trauma.

Abnormal and liquefied vitreous contributes significantly to the pathogenesis of retinal detachments in dogs. This, combined with violent head shaking (often with a chew toy) is the typical patient seen by our canine vitreo-retinal surgeons. The top 5 breeds are: Shih Tzu, Boston Terrier, Poodle, Yorkshire Terrier and Jack Russell Terrier. Dogs with this presentation carry the highest rate of success with early referral.



Partial retinal detachment with ventral retinal elevation

Cataract surgery has advanced with a success rate of 95% in most dogs. Retinal detachment can be a complication, but surgical correction is possible. Also, dogs who present for cataracts

where a retinal detachment is detected on ultrasound can have *simultaneous* cataract surgery and retinal reattachment surgery with good success. Traumatic retinal detachments, such as bite wounds, carry a lower success rate.

What does the veterinarian find on examination of the eye? The menace response is generally absent, unless part of the retina is still attached then the entire visual field is not lost. The pupillary light reflex (PLR) is present early on, but sluggish to absent with a chronic retinal detachment. The dazzle reflex is present. For your differentials, consider: SARD, IMR; discussed herein, optic neuritis or cortical blindness. In cases of SARD and IMR, the PLR is usually present. In cases of optic neuritis, the PLR is absent. Cortically blind dogs will retain a PLR.

On funduscopic examination, the retina may be billowing and out of focus when it is detached. The retina may also be hanging in a veil-like conformation covering up the optic nerve head. In those predisposed breeds, the vitreous may have dense white clumps and tendrils, mixed with pigment and blood clots.

Our veterinary ophthalmologists are always available to help you with your diagnosis and the best treatment plan for your patients.

Spotlight on

NEW LOCATIONS

ROCKVILLE, MARYLAND
1 Taft Court
Rockville, MD 20850

COLUMBIA, MARYLAND
8890 Centre Park Drive, Ste. 100
Columbia, MD 21045

ANNAPOLIS, MARYLAND
197 Defense Hwy, Suite 101
Annapolis, MD 21401

BEL AIR, MARYLAND
807 Baltimore Pike
Bel Air, MD 21014

TAMPA, FLORIDA
5406 Hoover Boulevard, Ste. 20
Tampa, FL 33634

LAKELAND, FLORIDA
3609 US Highway 98 South
Lakeland, FL 33803

WE'VE MOVED!

LEE'S SUMMIT, MISSOURI
New Address:
755 N.E. Anderson Lane
Lee's Summit, MO 64064

Congratulations!

Ronald Sigler, DVM, DACVO
Arizona Veterinary Medical Association
Veterinarian of the Year 2015

Community Award
to ECFA presented
by El Paso Veterinary Medical Association

Randall Scagliotti, DVM, MS, DACVO

Keynote Speaker for First China Veterinary College of Ophthalmology Conference

FOCUSING ON “THE BIG ROCKS”!

For the past twenty years I have referred to a company's key strategic initiatives as “the big rocks”. Big rocks are arrived at through a formal strategic planning process with the board or key members of the team, sometimes using a SWOT Analysis of strengths, weaknesses, opportunities and threats. The big rocks are documented and communicated so everyone knows what they are and regular updates illustrating progress are provided throughout the year.

Where did the term big rocks come from? You may recall a past college professor or lecturer sharing the big rocks story. A professor pulls out a wide-mouth

gallon jar and sets it on the table. About a dozen fist-size rocks are placed into the jar until it's filled to the top. The professor then asks, “Is the jar full?” The audience usually responds, “Yes”. Then the professor pulls out a bucket of gravel and small pebbles and dumps into the jar filling the spaces in between the fist size rocks and asks, “Is the jar full now?” The audience hesitates to respond yet some say “Yes”. The professor then pours sand into the jar to fill all the spaces and asks, “Can we get anything else in the jar?” Again, the audience hesitates but some say, “the jar is now full”. Finally, the professor takes a glass of water and pours it into the jar



Karen Webster, MBA
President & CEO, Eye Care for Animals

and asks, “What's the illustration here?” The point is if you don't put the big rocks in first you'll never get them all in. The lesson is don't get so caught up in the day to day minutia that you can't focus on the big rocks. Stay focused on the big rocks to ensure the key strategic initiatives are on target and completed in the coming year.

A PUBLICATION FOR THE VETERINARY COMMUNITY FROM EYE CARE FOR ANIMALS

OCULAR *Outlook*

PRESORTED
STANDARD
US POSTAGE
PAID
TUCSON, AZ
PERMIT #414

